

## An Ischemic Infarct in Medulla and Cervical Cord†

Ezzatollah Shivapour, MD\* and Gilbert B. Solitare, MD\*\*

*This report documents an unusual case of an occlusion of the anterior spinal artery of the medulla oblongata. The patient presented with involvement of the left accessory nerve and weakness of ipsilateral extremities. The diagnosis of an ischemic infarct in the distribution of the left proximal portion of the anterior spinal artery was made. Bulbar weakness, quadriplegia, and respiratory arrest developed. Postmortem examination, 23 days after onset, revealed an old infarct in the medulla which appeared as a more recent hemorrhagic infarct throughout the cervical cord.*

In 1908 Spiller described the clinical features of an infarct at the medullo-cervical area.<sup>1</sup> Two similar cases with postmortem findings have been reported by Davison.<sup>2</sup> To our knowledge, no other patients with a documented infarct in this locality have been reported. This paper describes the clinical and postmortem findings in a patient with an occlusion of the anterior spinal artery of the medulla oblongata.

### Case Report

A 44-year-old black woman developed sudden, severe frontal headache and weakness of the left arm and leg. She was admitted to the Henry Ford Hospital 24 hours later and was alert and able to talk. The presenting features were involvement of the XIth cranial nerve, paralysis of the ipsilateral extremities, and sparing of position sense. There was a flaccid paralysis of the left upper and lower limbs as well as profound weakness of the left sternocleidomastoid and trapezius muscles, but no other cranial nerves were involved. Palatal myoclonus was not present. Sensation was intact. The deep tendon reflexes were absent in the left upper and lower limbs and barely elicited on the right side. The plantar responses were flexor.

Past history was unremarkable, except for hypertension which had been present for many years and poorly controlled in spite of antihypertensive medications. The hemoglobin was 14.7 grams/100 ccs, and the white blood cell count was 8,400/cm.<sup>3</sup> VDRL was negative.

The day after admission, she developed weakness on the right side and difficulty clearing her throat that required frequent oral suctioning. Speech was nasal and the gag reflexes were depressed. Her responses to pin prick were diminished bilaterally, but the face was spared. The deep tendon reflexes were absent, although the plantar responses remained flexor. When lumbar puncture was performed, the fluid was clear and colorless. The opening pressure was 182 mm H<sub>2</sub>O. There were no cells. Protein was 107 mg %. Computerized tomography of the head was normal, as were films of the skull and cervical spine.

Weakness progressed, and she became quadriplegic with increasing difficulty in speech and swallowing. Tests for myasthenia gravis were negative. The neurological findings were unchanged except for the appearance of vertical and horizontal nystagmus and

† This paper received the first Annual HFH In-Training Manuscript Award.

Submitted for publication: October 2, 1978

Accepted for publication: December 11, 1978

\* Department of Neurology and Neurological Surgery, Division of Neurology, Henry Ford Hospital

\*\* Department of Pathology, Henry Ford Hospital

Address reprint requests to Dr. Shivapour, Division of Neurology, Henry Ford Hospital, 2799 W Grand Blvd, Detroit, MI 48202

bilateral extensor plantar responses. Treatment with dexamethasone 4 mg intramuscular every six hours was started.

While undergoing tracheal suction on the fourth day of hospitalization, she developed a respiratory arrest and was placed on a respirator. Subsequently, a tracheostomy was performed. Although the patient was able to initiate respirations, she required continued ventilatory assistance.

On the seventh day of hospitalization, she developed pneumonia, which responded to treatment with ampicillin. Dexamethasone was discontinued. The patient remained alert but was unable to talk and communicated by blinking. Her condition stabilized, respiratory assistance was maintained, and the neurological features did not change.

On the 20th day of hospitalization, she developed anemia which required blood transfusions. Hypotension, abdominal distention, and hypoactive bowel sounds occurred. A rectal tube was inserted, and melena was found. Two days later she developed pinpoint pupils, became increasingly lethargic, and died.

### Postmortem Findings

#### General

An acutely perforated duodenal ulcer with generalized

peritonitis was found. There was a recent large pulmonary infarct in the left lower lobe due to emboli.

#### Gross

The brain weighed 1,425 grams. Both vertebral arteries and a major portion of the basilar artery were not available for examination. No significant arteriosclerosis of the arteries at the base of the brain was present. There was flattening of the gyri and narrowing of the sulci with bilateral slight uncal notching.

No lesions were seen in the cerebrum, cerebellum and upper brain stem. A necrotic, focally hemorrhagic lesion extended from the lower medulla and throughout the cervical spinal cord (Figures 1 and 2). It involved the midventral aspect of the medulla and the left lateral aspect of the cervical cord and terminated abruptly at the cervico-thoracic junction. No abnormalities were noted in the thoracic and lumbar segments of the spinal cord.

#### Microscopic

Occasional pyknotic neurons with a slightly eosinophilic

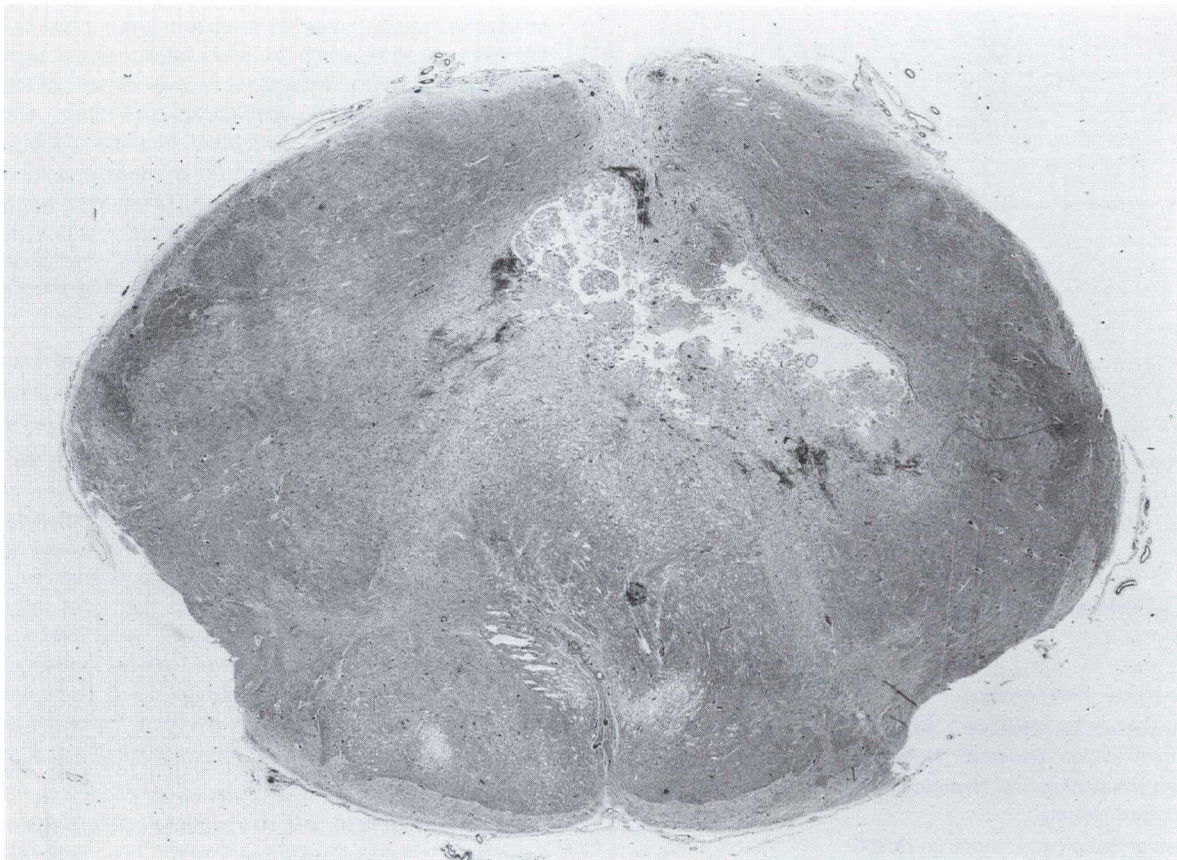


Fig. 1

Section through lower segment of the medulla. Ischemic infarct in left ventrolateral portion.

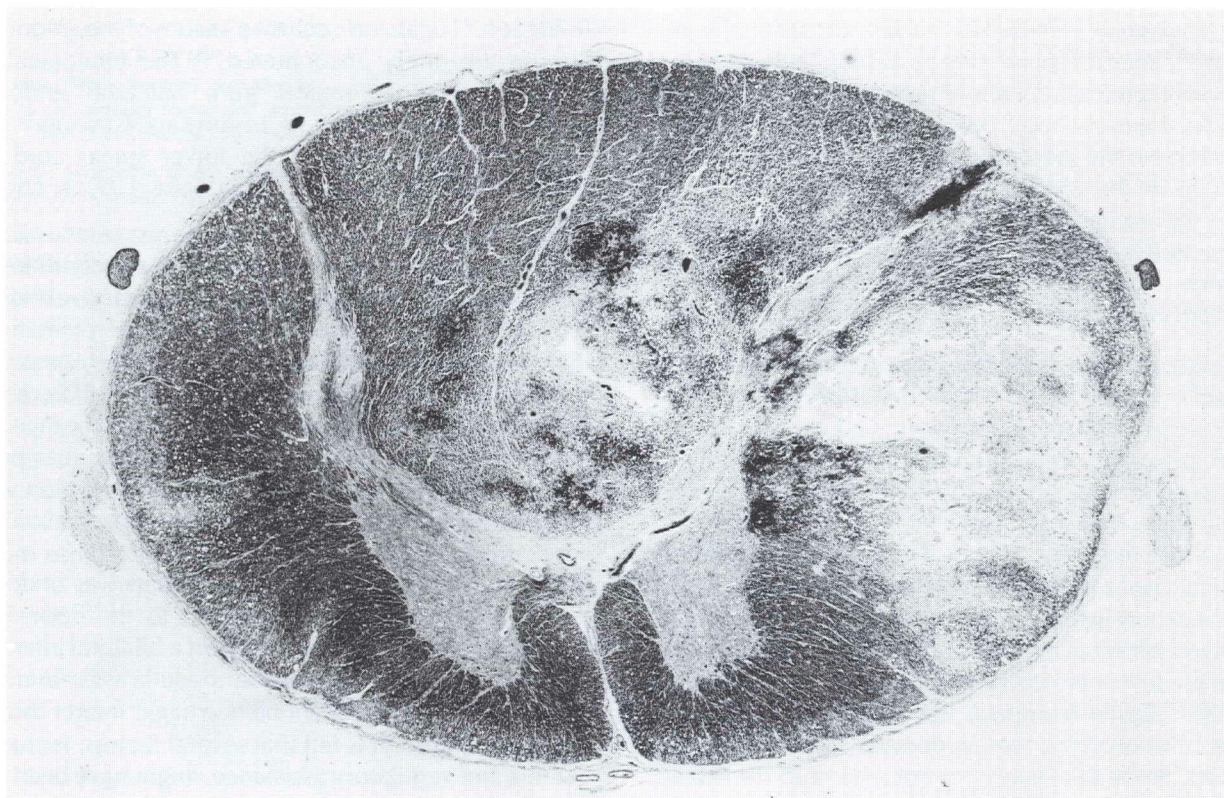


Fig. 2

Section through midsegment of cervical cord. Hemorrhagic infarct in left lateral portion.

cytoplasm were seen in the Sommer sector, as well as slight nuclear swelling of astrocytes.

The neurons of the cranial nerve nuclei and pontine nuclei in the lower portion of the pons were normal.

A large, subacute, ischemic infarct involved the entire midcentral portion of the medulla and the pyramidal decussations. The dorsal cranial nerve nuclei were spared. A few petechiae and innumerable macrophages, primarily nonpigmented, were seen throughout this infarct along with some perivascular lymphocytic infiltrates.

Sections from the uppermost portion of the cervical cord and from the cervical enlargement disclosed no abnormalities among the nerve roots or within the leptomeninges. A large region of subacute necrosis involved primarily the ventral portions of the dorsal columns and the lateral white matter on the left. It contained numerous macrophages, both pigmented and nonpigmented, as well as a relatively recent hemorrhage. The white matter of the lateral corticospinal tracts as well as of the spinocerebellar tracts was coarsely vacuolated (indicative of myelin-destruction). A few swollen neurons were seen in the anterior horns. The ventral white matter was normal.

The thoracic and lumbar spinal cord, nerve roots, and leptomeninges were normal.

### Discussion

The lower portion of the medulla oblongata is supplied by branches from the vertebral arteries and the proximal portions of the posterior, inferior, cerebellar, and anterior spinal arteries.<sup>1</sup> The anterior spinal artery supplies the ventral and mid portions of the medulla, which includes the pyramid, medial lemniscus, tectospinal tract, and posterior longitudinal bundle. Occasionally, the ventral portion of the inferior olivary nucleus, hypoglossal, vagus and accessory nerves is also supplied by these arteries. More often, however, these cranial nerves are supplied, along with other structures in the lateral portion of the medulla, by branches from vertebral and posterior inferior cerebellar arteries.<sup>1,2</sup>

When the anterior spinal artery of the medulla is occluded, the symptoms consist of contralateral weakness and loss of position sense resulting from destruction of the corticospinal tract and medial lemniscus.<sup>1,2</sup> The tongue is usually spared. The extent of the lesion varies with the distribution and caliber of the anterior spinal artery, but the proximal left

anterior spinal artery is frequently larger. Occasionally, the proximal right anterior spinal may be absent. In these cases, occlusion of this remaining artery results in infarcts of both corticospinal tracts and medial lemnisci with bilateral signs. Usually, the proximal anterior spinal arteries arise 0.75 to 1 cm proximal to the origin of the basilar artery. The two anterior spinal arteries may then descend for less than one to several cms before uniting to form the single anterior spinal artery, which is located in the anterior median fissure of the medulla and spinal cord.

Unfortunately, in our patient the arteries in this region were not available. In view of her initial unilateral neurological deficit, it is believed that the original occlusion was confined to the left proximal anterior spinal artery. The profound weakness of sternocleidomastoid and trapezius muscles on the left side indicated involvement of the accessory nerve, which localized the lesion to the lower medulla and uppermost cervical cord on the left side (Figure 1). Of interest also was the weakness of left upper and lower limbs, which implied involvement of the corticospinal tract after decussation at the medullo-cervical junction. Furthermore, since at this level the medial lemniscus has not formed, the tracts conveying position sense remain dorsally situated and thus were spared. Since the lesion did not extend to the lateral segments, the spinothalamic tract, nucleus and spinal tract of the trigeminal nerve remained uninvolved. Accordingly, it was assumed that the lesion was confined to the central region, and in all probability, the initial infarct was in the distribution of the left proximal anterior spinal artery.

Nystagmus has been described in patients with medullary infarcts due to anterior spinal artery disease.<sup>2</sup> We believe this to be the cause of the nystagmus in our patient in spite of the fact that it has also been reported in patients with high cervical cord lesions of the spinovestibulo-cerebellar pathways.<sup>3</sup>

The upper portion of the medulla is perfused by paramedian branches from the rostral portion of the vertebral arteries and the adjacent segment of the basilar artery. Ischemic lesions of these vessels are usually associated with sudden, severe vertigo and vomiting. The patient remains conscious, but usually falls because of weakness in the lower limbs. Nystagmus develops as well as ataxia of ipsilateral extremities. There is numbness of ipsilateral face and contralateral extremities, and the tongue is invariably involved. In our patient, the absence of vertigo, vomiting, ataxia, and sparing of the tongue were atypical for a lesion at this level of the medulla.

Most instances of infarction in anterior spinal artery distribution are confined to the thoracic cord<sup>4,5</sup> and have been associated with dissecting aneurysms of the aorta,<sup>6</sup> complications of aortic surgery,<sup>7</sup> cardiac arrest,<sup>8</sup> and myocardial

infarction.<sup>9</sup> Localized occlusive lesions of the anterior spinal arteries are rarely encountered.<sup>4,5</sup> The etiological factors included syphilis, emboli from bacterial endocarditis, trauma, and atherosclerosis. Laguna and Craviota<sup>10</sup> recently reported an infarction of the lower spinal cord due to occlusion of the anterior spinal artery by a cholesterol embolus.

In our patient, there was no evidence of any condition which might have precipitated the ischemic infarct, although she did have poorly controlled hypertension of many years' duration. Forty-eight hours after onset, her weakness became bilateral with bulbar involvement. A bilateral sensory deficit to pin prick occurred with sparing of the face. Shortly thereafter, she became quadriplegic with bulbar paralysis. Respiratory arrest developed. Tracheal intubation was performed immediately, and the patient was maintained on ventilatory assistance. The occurrence of these more profound and bilateral neurological deficits was undoubtedly due to an extension of the infarct to the opposite side. Indeed, at postmortem examination a bilateral infarct involving the central portion of the medulla was found which extended as a more recent hemorrhagic infarct throughout the cervical cord. It is felt that several factors, including the anemia and ventilatory assistance, might have been responsible for the spread of this infarct into the cord.

### Acknowledgments

The authors wish to thank Dr. J. L. Chason and Dr. R. D. Teasdall for reviewing this manuscript.

## Ischemic Infarct in Medulla and Cervical Cord

### References

1. Spiller WG: The symptom complex of a lesion of the uppermost portion of the anterior spinal and adjoining portion of the vertebral arteries. *J Nerv Ment Dis* **35**:775, 1908.
2. Davison C: Syndrome of the anterior spinal artery of the medulla oblongata. *Arch Neurol Psychiat* **37**:91, 1937.
3. Rand RW and Rand CW: *Intraspinal Tumors of Childhood*. Springfield, Ill, Charles C Thomas, 1960.
4. Henson RA and Parsons M: Ischaemic lesions of the spinal cord. *Quart J Med* **36**:205-222, 1967.
5. Garland H, Greenberg J, and Harriman DGF: Infarction of the spinal cord. *Brain* **89**:645-662, 1966.
6. Thompson GB: Dissecting aortic aneurysm with infarction of the spinal cord. *Brain* **79**:111-118, 1956.
7. Zuber WT, Gasper MR, and Rothschild PD: The anterior spinal artery syndrome, a complication of abdominal aortic surgery. *Ann Surg* **172**:909-915, 1970.
8. Gilles FH and Nag D: Vulnerability of human spinal cord in transient cardiac arrest. *Neurology (Minneap)* **21**:833-839, 1971.
9. Madow L and Alpers BJ: Involvement of the spinal cord in occlusion of the coronary vessels. *Arch Neurol Psychiat* **61**:430-440, 1949.
10. Laguna J and Cravioto H: Spinal cord infarction secondary to occlusion of the anterior spinal artery. *Arch Neurol* **28**:134-136, 1973.

